

The Micro-Implant Pearl

A. KORRODI RITTO, DDS, PHD

The Lingual Pearl is a passive-guidance appliance used primarily to retrain patients' tongue function and for speech therapy.¹ It also can be used in orthodontic treatment when it is important to correct the position of the tongue at rest and during swallowing. The Lingual Pearl can be attached to a transpalatal bar, a Quad Helix,* a thermoformed splint, or a wire bonded to the lingual surfaces of the premolars. Because of its versatility with either removable or fixed appliances, the Pearl can be applied at any time during or after orthodontic treatment.

A drawback of the fixed Lingual Pearl during orthodontic treatment is the frequent need for tooth movement at sites where the device may be attached, such as the upper first premolars. The solution for this problem is to attach the Pearl to a palatal micro-implant, which led me to design the Micro-Implant Pearl (MIP).

The size of the acrylic bead is an important consideration when using either the Lingual Pearl or MIP. Many similar appliances sold commercially feature a bead that is too large. For speech therapy and deglutition reeducation, the MIP should be small enough to serve simply as a reference point for proper tongue placement. The bead should not exceed 2mm in diameter, and the tongue tip should be able to touch the bead and the palatal tissue simultaneously. Construction should allow for movement in as many planes as possible

*Rocky Mountain Orthodontics, 650 W. Colfax Ave., Denver, CO 80204; www.rmortho.com.



Dr. Ritto is in the private practice of orthodontics at Rua Capitão Mouzinho Albuquerque 115 1, Leiria, 2400-194 Portugal; korrodi@gmail.com. He is the inventor of the Lingual Pearl and MIP.

to maximize tongue conditioning.

For orthodontic therapy, the Pearl can be slightly larger—1.5-3mm in diameter. It can be placed during initial treatment, when the tongue is the sole etiological factor in the development of malocclusion. After correction of an open bite or space closure, the MIP can help prevent the tongue from reverting to the conditions under which the original abnormality developed. Surgical patients can also benefit from the MIP, considering the abrupt alteration in the amount of space available for the tongue, especially in open-bite cases.




Fig. 1 MIP 1, with Lingual Pearl on square wire bonded to cap of joint-head micro-implant.

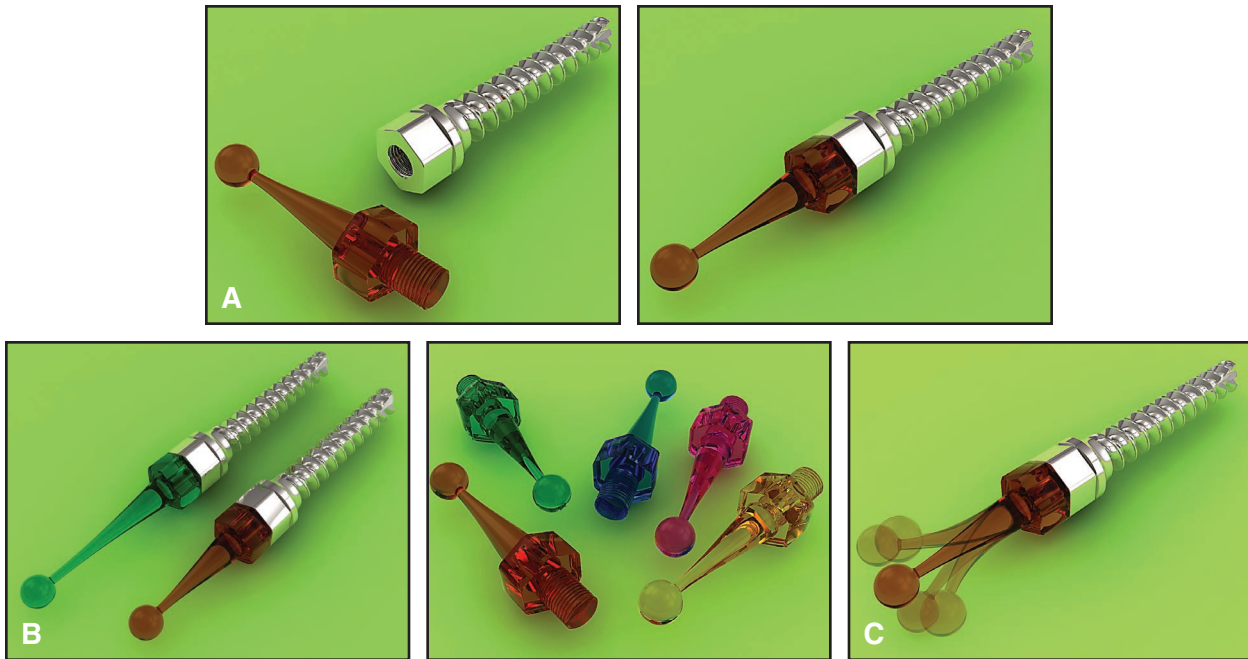

Fig. 2 A. Prototype of MIP 3, or “tongue joystick” system, providing greater elasticity and freedom of movement. B. MIP 3 in different lengths and colors. C. Possible range of motion.

Speech and Deglutition Therapy

Three versions of the Micro-Implant Pearl have been developed. The MIP 1, intended for use in speech and swallowing therapy, features an acrylic bead on a rectangular wire, which is attached to the cap of a Dentos joint-head mini-implant** (Fig. 1). This design is being replaced by the MIP 3 (Fig. 2), a flexible silicone version being tested by the author and Dr. Hee-Moon Kyung, to be made available later this year. The silicone MIP 3 or “tongue joystick” will be extremely elastic, offering even more possibilities for tongue movement and reeducation.

Diction-related problems have a multifaceted etiology that includes anatomical, psychological, and mental factors. The degree of severity can range from slight difficulty in the correct pronunciation of individual words to total inability to articulate sounds, words, and sentences. Considering that malocclusions are closely linked to lingual function, orthodontic treatment can represent an important adjunct to speech therapy. A cross-disciplinary treatment plan is the best strategy. Speech therapy can include simple muscular exercises, pronunciation of consonants, or production of sounds, melodies, words, and phrases (Fig. 3).

Orthodontic Treatment

The MIP 2 is similar to the MIP 1 in that it incorporates a joint-head micro-implant, but in this case the acrylic bead is attached to a nylon screw*** that inserts into the cap of the metal miniscrew (Fig. 4). The Pearl can move up, down, and laterally and thus serve as a reference point to help a patient determine the correct location for the tip of the tongue.

The following case report shows successful open-bite treatment using the MIP 2.

Case Report

A 13-year-old male patient presented with a Class III malocclusion, anterior and posterior crossbite, ectopically erupted upper canines, and severe maxillary crowding (Fig. 5A). After extraction of the upper premolars, fixed appliances were bonded in the upper arch, and Class III elastics were used to correct the anterior crossbite. An open bite and lower spacing then appeared because

**Joint-head micro-implants, Part Nos. JL1514-05, JL1514-06; screwdriver, Part No. LHD-OB-L; Dentos Co. Ltd, Galsan-Dong, Dalseo-Gu, Daegu 704-900, Korea; www.dentos.kr.

***Available from the author.

Consonants

Palatal: /l/, /n/, /t/

Tip of tongue should rest on Lingual Pearl.

Long consonants: /s/, /z/ (sssss, zzzz)

Tip of tongue is positioned in front of Pearl.

Words

/ts/

“church”, “children”

/dz/

“jazz”, “jump”

Sounds

Ta

Tip of tongue rotates Pearl backward.

Tla

Tip of tongue rotates Pearl forward.

Melodies

Ta ra ta ra / Tic tac tic tac

Tip of tongue rotates Pearl both backward and forward.

Phrases

Alveolar: /l/, /s/

“Lazy Sue, lonely Sally”

Palatoalveolar: /r/

“Rick rode in a red car”

Dental: /ð/

“The mother and father”

Fig. 3 Speech-therapy exercises for tongue reeducation with MIP. (Movie clips showing author's recommended exercises can be accessed from online version of this article at www.jco-online.com.)

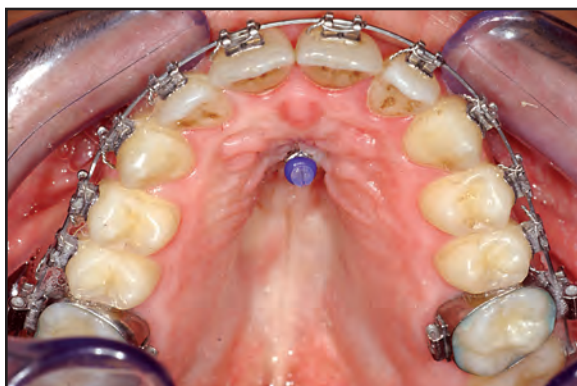


Fig. 4 MIP 2 with nylon screw fixing Pearl in cap of joint-head mini-implant.

of the patient's low tongue position (Fig. 5B).

The MIP 2 was placed in the palate (Fig. 5C), and appropriate exercises were explained to the patient. After three months, the anterior open bite was closed, and the spacing had disappeared without any additional use of elastics (Fig. 5D).

The MIP 2 was left in place for four months after removal of the fixed appliances (Fig. 5E).

Discussion

No breakage or failure of the MIP has been observed to date. Failure of the miniscrew is much more likely and was one of the reasons for development of the silicone MIP 3. This flexible “tongue joystick” will greatly reduce the force transmitted to the miniscrew during tongue exercises and movement.

It should be noted that placement of an implant in the midpalatal suture carries risks to the development of the suture in the deciduous or mixed dentition. For younger patients, the traditional, toothborne Lingual Pearl is recommended.

(continued on next page)

REFERENCES

1. Ritto, A.K. and Leitão, P.: The Lingual Pearl, *J. Clin. Orthod.* 32:318-327, 1998.

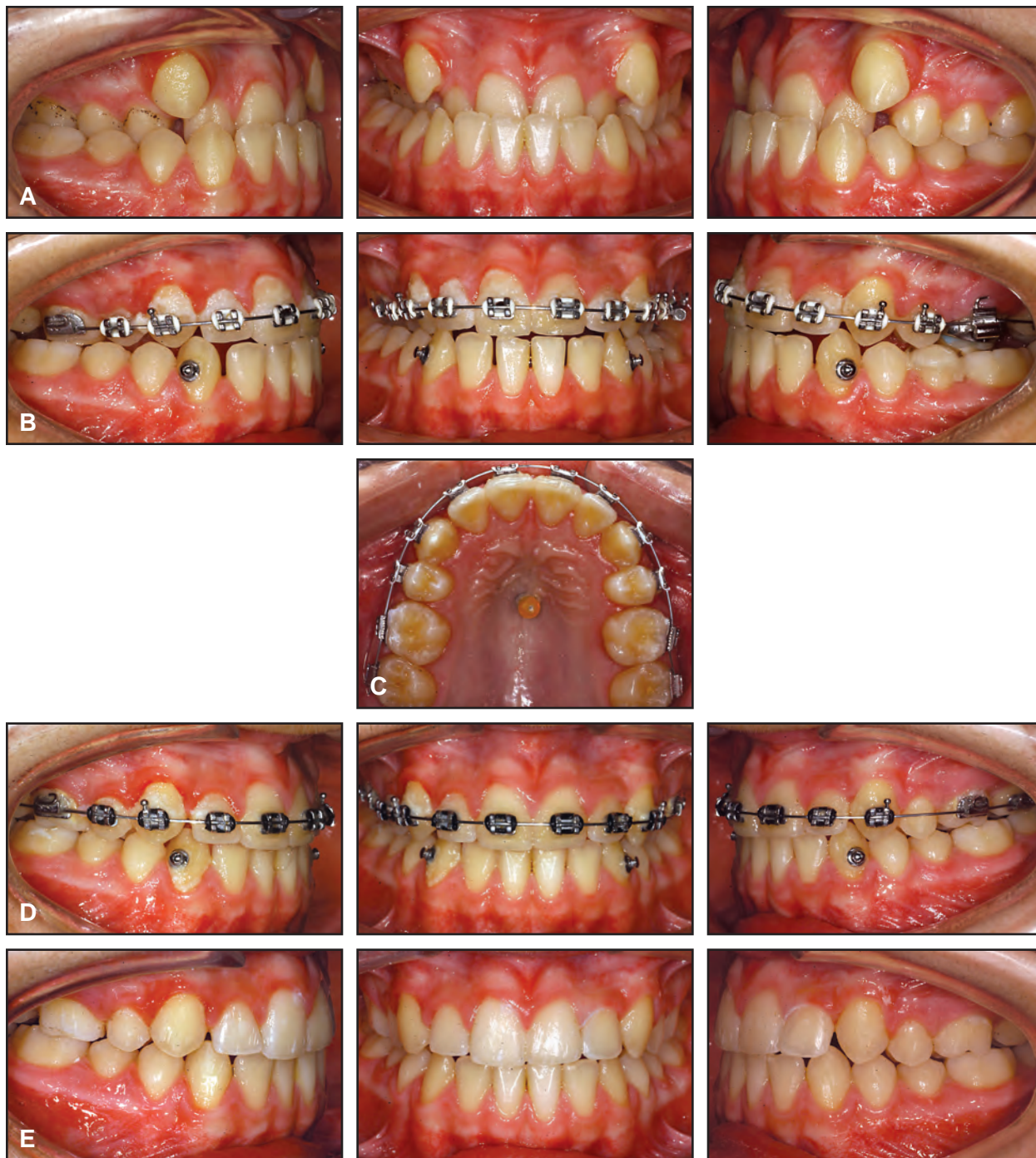

Fig. 5 A. 13-year-old male patient with anterior crossbite treated with maxillary fixed appliances and Class III elastics. B. After correction of crossbite, patient exhibited open bite and lower spacing from low tongue position. C. MIP 2 placed in palate for tongue reeducation. D. Three months later, bite and diastemas closed without use of elastics. E. MIP left in place for four months after removal of appliances.